

Efficacy of fractional CO₂ laser treatment in postmenopausal women with genitourinary syndrome: a multicenter study

Maurizio Filippini, MD,¹ Daniela Luvero, MD,² Stefano Salvatore, MD,³ Annalisa Pieralli, MD,⁴ Roberto Montera, MD,² Francesco Plotti, MD,² Massimo Candiani, MD,³ and Roberto Angioli, MD²

Abstract

Objective: Genitourinary syndrome of menopause (GSM), especially vulvovaginal atrophy (VVA), is one of the most common conditions among women in either natural (4%-47%) or medically induced (23.4%-61.5%) menopause. The aims of this study are to assess the efficacy and effectiveness of CO₂ laser in postmenopausal women with clinical signs and symptoms of GSM, in particular VVA, and to evaluate both possible early and late side effects related to this kind of treatment.

Methods: This retrospective, multicenter study was conducted after collecting data from a pre-existing database. We performed three to four CO₂ laser treatments on all the women enrolled in this protocol. We used a fractional CO₂ laser system (SmartXide² V²LR, Deka m.e.l.a., Florence, Italy) with a VulvoVaginal Laser Reshaping (V²LR) scanning system and appropriate handpieces for the vaginal area. All women before and after the treatment were assessed. The pre- and post-treatment averages of the symptoms, the standard deviation, and the *P* values were calculated.

Results: Six hundred forty-five women who met the inclusion criteria were considered. In all the parameters examined (dyspareunia, vaginal orifice pain, dryness/atrophy, itching, burning, pH) statistically significant data were found between the pretreatment and the post-treatment (dryness: before = 8.30, after = 2.97 [*P* < 0.0001], dyspareunia: before = 8.70, after = 3.51 [*P* < 0.0001]; burning: before = 6.12, after = 1.78 [*P* < 0.0001]; vaginal orifice pain: before = 8.07, after = 2.94 [*P* < 0.0001]; itching: before = 6.09, after = 1.32 [*P* < 0.0001]).

Conclusions: Our results show the effectiveness and a good degree of tolerance of treatment with the CO₂ laser system in postmenopausal women with GSM.

Key Words: CO₂ laser – Genitourinary syndrome of menopause – Menopause – Postmenopausal symptoms – Vaginal atrophy – Vaginal laser therapy.

Genitourinary syndrome of menopause (GSM), especially vulvovaginal atrophy (VVA), is one of the most common conditions among women in natural (4%-47%) or medically induced (23.4%-61.5%) menopause.¹ The vulvovaginal tract is modified both structurally and functionally due to the decline of estrogen: the dehydrated epithelium gets thinner, vaginal walls become less elastic, the pH significantly increases, opening the door to attack by pathogenic bacteria and infections (high pH). As a result, women may present with some or all of the clinical signs and symptoms: vaginal laxity, dryness (83%), dyspareunia (42%),

itching (26%), burning (14%), urinary incontinence (30%), infections (17%), pain at the vaginal orifice (11%), and recurrent bleeding.² Vaginal atrophy can worsen over time and reduce quality of life. In fact, 75% of women report a significant reduction of their quality of life,^{2,3} increased social isolation (13%), loss of self-esteem (26%), and more difficulty with partner intimacy (40%).³

Nowadays, around 50% of women suffer from these symptoms during menopause.^{2,4} Therefore, it is important to improve this condition to increase women's well-being. The therapeutic options for VVA include nonhormonal local therapies (ie, lubricants, moisturizers) and hormonal ones (ie low-dose vaginal estrogen) that can be used either together or alternatively.⁵ Lubricants and moisturizers offer temporary relief from vaginal symptoms and can improve lubrication but they have no effect on the overall Vaginal Maturation Index/value.⁶ Lubricants and moisturizers are less effective than local hormone therapy (60% vs 84%).^{7,8}

Systemic hormone therapy (HT) is recommended in women who are referred with vaginal symptoms and hot flashes and protects women from osteoporosis. Currently local administration of estrogen is the gold standard: in particular, it is recommended for women with vaginal

Received February 23, 2019; revised and accepted July 16, 2019.

From the ¹Department of Obstetrics and Gynecology, Hospital State of Republic of San Marino, San Marino, Republic of San Marino; ²Department of Obstetrics and Gynecology, Campus Bio-Medico University, Rome, Italy; ³Department of Obstetrics and Gynecology, IRCCS San Raffaele Hospital, Milan, Italy; and ⁴Department of Obstetrics and Gynecology, Department of Woman and Child Health, Careggi University Hospital, Florence, Italy.

Funding/support: None reported.

Financial disclosures/conflicts of interest: None reported.

Address correspondence to: Daniela Luvero, MD, Department of Obstetrics and Gynecology, Campus Bio-Medico University, Via Alvaro del Portillo 200, Rome. E-mail: d.luvero@unicampus.it

symptoms. Its use is controversial, due to the systemic adsorption of the estrogen.⁹

Laser therapy is a new non-hormonal treatment for the prevention and management of VVA. There are many kinds of lasers: CO₂, Erbium Yag, and Neodimium Yag. Current literature includes 22 laser studies,¹⁰⁻³¹ 17 (77.27%)^{10,11,17-30,32} regarding the efficacy of the CO₂ laser in the treatment of VVA with a maximum follow up of 25 months.^{10,11,17-30,32} In this study the CO₂ laser was analyzed because it is the most well-documented in the literature.

The fractional CO₂ laser reaches deeper layers to reinvigorate collagen and extracellular matrix synthesis and consequently engendering tissue trophism recovery. The CO₂ laser has been successfully used for dermatologic pathologies such as lichen, condylomas, and fibroids. Recently, the literature has demonstrated good results for female genital functionality and clinical improvement of symptoms supported by pathology reports of studies before and after treatment.^{25,29,31}

The aims of this observational study are to assess the efficacy and effectiveness of the CO₂ laser in postmenopausal women with clinical signs and symptoms of VVA and to evaluate both possible early and late side effects related to this kind of treatment.

METHODS

Women from four centers were screened for our retrospective study:

- Gynecology Department of Università Campus Biomedico, via Alvaro del Portillo, 200, Rome.
- Gynecology Department of Ospedale di Stato della Repubblica di San Marino, San Marino.
- Gynecology Department of Azienda Ospedaliera Careggi, Largo Brambilla, 3, Florence.
- Gynecology department of Ospedale San Raffele, Via Olgettina, 60, Milan.

This multicenter study was conducted by collecting data from a pre-existing database. The reference period for the analysis was from November 1, 2012 to February 14, 2018. The study was approved by the local ethics committee with protocol number 14/18 OSS.

Before treatment all patients underwent gynecological examination and urinalyses, VAS (Visual Analog Scale 0-10) to evaluate vaginal atrophy and related symptoms, pH, and, optionally, the Vaginal Health Index Score (VHIS), and vaginal swab to screen for infections. If women were symptomatic for any infection, they started a preventive therapy with vaginal lactobacillus.

The data of all the women were analyzed based on the inclusion and exclusion criteria. The inclusion criteria were:

- Menopausal status
- Women with more than one vulvovaginal symptom and VAS evaluation before and after the treatment
- Three to four CO₂ laser treatments
- Between 18 and 75 years old
- Vaginal atrophy
- No uncontrolled psychiatric disorders
- No symptomatic genital infections

- No stenosis, trauma, or necrosis of the urethra
- Eastern Cooperative Oncology Group performance status less than 2

The exclusion criteria were:

- Pregnancy
- Hematuria or urine clotting
- Alcohol or drug addictions
- Abscess, fistula, or any anatomical abnormality that could interfere with treatment
- Prolapse stage higher than 2 according to the Pelvic Organ Prolapse Quantification System (Baden and Walker)
- Use of any form of local therapy within the previous 15 days

All women signed an informed consent form.

Three or 4 CO₂ laser treatments were administered to all the women enrolled in this protocol:

- to treat vaginal atrophy: power 40 W, scan time 1000 μ s, spacing 1000 μ m, Smart stack 1/2
- to treat vulvar atrophy: power 25 W, scan time 500 μ s, spacing 500 μ m, Smart stack 1

A fractional CO₂ laser system was used (SmartXide²V²LR, Deka m.e.l.a., Florence, Italy) with a VulvoVaginal Laser Reshaping (V²LR) scanning system and appropriate handpieces for the vaginal area. This treatment modality is based on the interaction between a specific CO₂ pulsed laser and the vaginal mucosa. A laser beam is emitted fractionally, and the CO₂ laser is focused on small spots (called DOTs) that are separated by healthy tissue. Every pulse consists of constant high-energy peak power to produce rapid ablation of the epithelial component of the atrophic mucosa, followed by longer emission times that allow the CO₂ laser to penetrate further into the mucosa.

The pulses are distributed over the vaginal wall and are spaced (DOT spacing) to cover the entire treatment area. A specific handpiece is used to deliver the pulses, emitting energy at 360°. To treat the vaginal area completely, it is necessary to emit many laser spots while progressively extracting the handpiece from the vaginal fundus. Each treatment spot consists of two steps. After the first energy release, the handpiece is rotated approximately 2 cm (using the tool) clockwise while remaining at the same vaginal distance. During all treatment sessions, the following two-phase protocol was followed; initial positioning of the speculum and observation of the vagina, then careful introduction of the handpiece deep into the vaginal canal before starting the procedure.

Each session lasted 5 to 6 minutes. No local therapy was recommended during or after the laser sessions.

A gynecological examination, physical chemical examination of urine, urinalysis, VAS (0-10) evaluation of vaginal atrophy and related symptoms, pH testing with optional VHIS evaluation, and vaginal swab to screen for infections were performed on each woman.

After the CO₂ laser treatment, all women underwent annual periodic examinations to evaluate the presence or absence of symptoms (burning, itching, dryness, etc). Periodic checks

FRACTIONAL CO₂ LASER TREATMENT IN MENOPAUSE

TABLE 1. Demographic characteristics

Patients enrolled	645 (53.17%)
Median age	56 ± 7.9 yr
Median age of menopause	48 ± 5.6 yr
Patients with natural menopause	521/645 (80.7%)
Patients with medical induced menopause	124/645 (19.22%)
Oncologic patients	171/645 (26.5%):
	134 with breast cancer
	18 with gynecological cancer
	16 with no gynecological cancer
	4 with no specified cancer

were scheduled each month, during the treatment, at the end of the treatment, after 6 to 12 months and then once a year depending on the protocol used. During the follow-up women underwent a gynecological examination and were administered a questionnaire to answer on the presence or absence of symptoms. In this study, the VAS was considered before the first session of laser treatment and 1 month after the last laser treatment session.

INSTAT3 program was used for statistical analysis. The pre- and post-treatment averages of the symptoms, standard deviation, and *P* value were calculated. Moreover, an additional “two-tailed *P* value” analysis was done using the Mann-Whitney test. In this study no control group was used because it is a retrospective study. We collected data from existing databases to evaluate the effectiveness of laser treatment; we did not aim to compare superiority over a control group

RESULTS

A total of 1,213 women were examined in the study:

- Ninety-one (8.16%) from the database of the Gynecology Department of Università Campus Biomedico, via Alvaro del Portillo n 200, 00128, Rome- Italy;
- Five hundred ninety (48.64%) from the database of the Gynecology Department of Ospedale di stato della Repubblica di San Marino, via la Toscana 1, San Marino, Repubblica di San Marino;
- Three hundred twenty-three (26.63%) from the database of the Gynecology Department of Azienda Ospedaliera Careggi, Largo Brambilla, 3, Florence, Italy;
- Two hundred one (16.57%) from the database of the Gynecology Department of Ospedale San Raffele, Via Olgettina, 60 Milan, Italy.

We screened the inclusion and exclusion criteria and then enrolled 645 women (53.17%) of which:

- Fifty (7.75%) from the database of Rome;

- One hundred seventeen (18.14%) from the database of Milan;
- Two hundred fifty-five (39.53%) from the database of Florence;
- Two hundred twenty-three (34.57%) from the database of San Marino.

All demographic characteristics of the participants are listed in Table 1.

For all 645 women atrophy was evaluated before and after treatment using the VAS. Vulvar atrophy shows as dry, pale mucosa with a feeling of burning and itching; therefore, the diagnosis is made under gynecological exam.

Other symptoms besides dryness were evaluated in the same women. In particular:

- pH: 299 women (46.36% of all women enrolled)
- Dyspareunia: 611 women (94.76% of all women enrolled)
- Vaginal orifice pain: 238 women (36.90% of all women enrolled)
- Dryness/atrophy: 645 women (100% of all women enrolled)
- Itching: 257 women (39.84% of all women enrolled)
- Burning: 293 women (45.43% of all women enrolled)

The mean time of treatment was 6.5 ± 3.1 months from the beginning of the first session to the end of the last session. One hundred seventy-one (26.5%) of the 645 women recruited were oncology patients as shown in Table 1.

Of all the parameters examined (dyspareunia, vaginal orifice pain, dryness/atrophy, itching, burning, pH) (Table 2) statistically significant data were found between pretreatment and post-treatment. The statistically significant difference and the average of the VAS before and after treatment are summarized in Figure 1 (dryness: before = 8.30, after = 2.97 [*P* < 0.0001]; dyspareunia: before = 8.70, after = 3.51 [*P* < 0.0001]; burning: before = 6.1, after = 1.78 [*P* < 0.0001]; vaginal orifice pain: before = 8.07, after = 2.94 [*P* < 0.0001]; itching: before = 6.09, after = 1.32 [*P* < 0.0001]). The logarithmic scale was also evaluated: pH: before = 5.82, after = 5.61 (*P* < 0.0001).

The 645 women recruited were subdivided into two subgroups based on the number of treatment cycles they received. Five hundred ninety-five women who underwent three sessions and fifty women who underwent four sessions.

Statistical significance was maintained in the two subgroups as shown in Figure 2 for the women receiving three cycles (dryness: before = 8.26, after = 2.92 [*P* < 0.0001]; dyspareunia: before = 8.65, after = 3.44 [*P* < 0.0001]; burning: before = 6.06, after = 1.71 [*P* < 0.0001]; vaginal orifice pain:

TABLE 2. Symptoms pre- and post-treatment

Sign/symptoms	No Pz	%	Pretreatment	Post-treatment	<i>P</i>
pH	299	46.36	5.82	5.61	<0.0001
Dyspareunia	611	94.73	8.70	3.51	<0.0001
Pain at the vaginal orifice	238	36.90	8.07	2.94	<0.0001
Dryness/atrophy	645	100.00	8.30	2.97	<0.0001
Itching	257	39.84	6.09	1.32	<0.0001
Burning	293	45.43	6.12	1.78	<0.0001

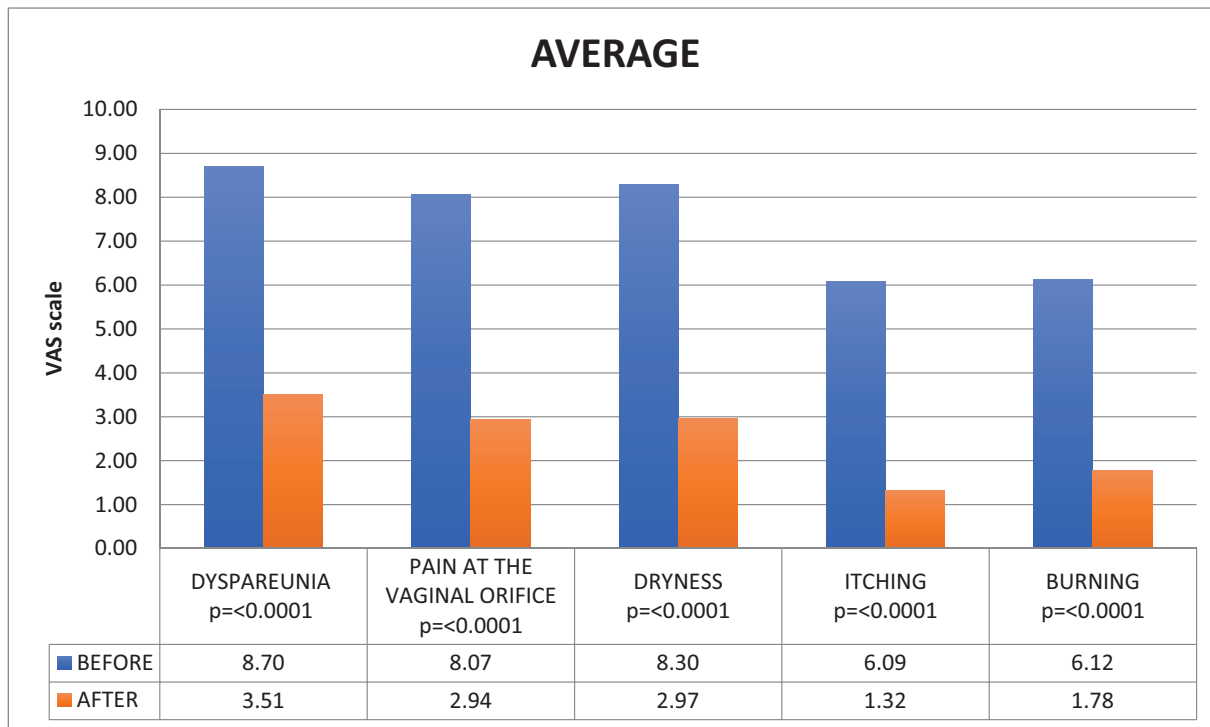


FIG. 1. The average VAS symptoms before (in blue) and after (in red) three or four laser treatments. VAS was considered before the first laser treatment session and 1 month after the last laser treatment session. Treatment (Dryness: before = 8.30; after = 2.97 [$P < 0.0001$]). Dyspareunia: before = 8.70; after = 3.51 [$P < 0.0001$]. Burning: before = 6.12; after = 1.78 [$P < 0.0001$]. Vaginal orifice pain: before = 8.07; after = 2.94 [$P < 0.0001$]. Itching: before = 6.09; after = 1.32 [$P < 0.0001$]). VAS, Visual Analog Scale.

before = 7.84, after = 2.60 [$P < 0.0001$]; itching: before = 6.09, after = 1.33 [$P < 0.0001$]; pH: before = 5.59, after = 5.53 [$P < 0.0001$]) and Figure 3 for the women who had four cycles (dryness: before = 8.09, after = 3.18 [$P < 0.0001$]; dyspareunia: before = 8.52, after = 3.64 [$P < 0.0001$]; burning: before = 6.27, after = 2.09 [$P < 0.0001$]; vaginal orifice pain: before = 7.99, after = 3.23 [$P < 0.0001$]; itching: before = 6.06, after = 1.68 [$P < 0.0001$]; pH: before = 6.08, after = 5.72 [$P < 0.0001$]).

The percentages of improvement of the 645 women were: dyspareunia 60%, dryness 64%, burning 71%, vaginal orifice pain 64%, and itching 78% (Fig. 4). The delta of improvement was then compared for two of the subgroups: a superior improvement of the symptoms such as dryness (65% vs 61%), itching (78% vs 72%), burning (72% vs 67%), and vaginal orifice pain (67% vs 60%) was found in the group that received three cycles in comparison to the group that received four cycles. With regard to pH, the group that received four cycles performed better in comparison to the group that received only three cycles (1% vs 6%). These data are statistically significant. No side effects were observed in any of the CO₂ laser sessions. The side effects were evaluated as pain greater than VAS 6 either after or during the treatment, problems in sexual function either after or during the treatment, the presence of abrasions or ulcerations after the laser treatment. Patients did not report any of these side effects. Only 6% of the total 1,213 women treated repeated the therapy cycle after 20 months (range 8-32 months).

DISCUSSION

GSM, particularly VVA is one of the most common conditions in postmenopausal women¹ because the vulvovaginal tract is closely related to estrogen reduction, with a consequent decline in the quality of life. Approximately 50% of menopausal women suffer from^{4,26} vaginal laxity, dryness (83%), dyspareunia (42%), itching (26%), burning (14%), urinary incontinence (30%), infections (17%), pain at the

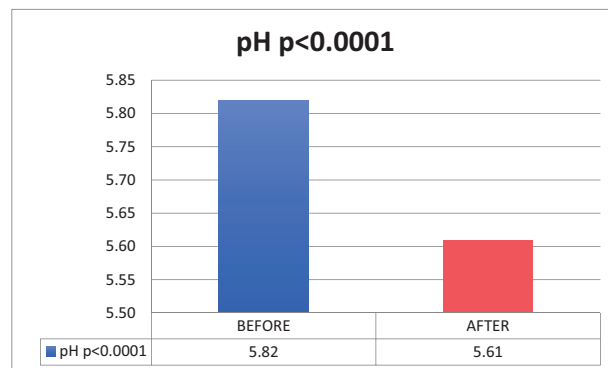


FIG. 2. The average VAS symptoms before (in blue) and after (in red) three or more laser treatments. VAS was considered before the first laser treatment session and 1 month after the last laser treatment session. (Dryness: before = 8.26; after = 2.92 [$P < 0.0001$]). Dyspareunia: before = 8.65; after = 3.44 [$P < 0.0001$]. Burning: before = 6.06; after = 1.71 [$P < 0.0001$]. Vaginal orifice pain: before = 7.84; after = 2.60 [$P < 0.0001$]. Itching: before = 6.09; after = 1.33 [$P < 0.0001$]).

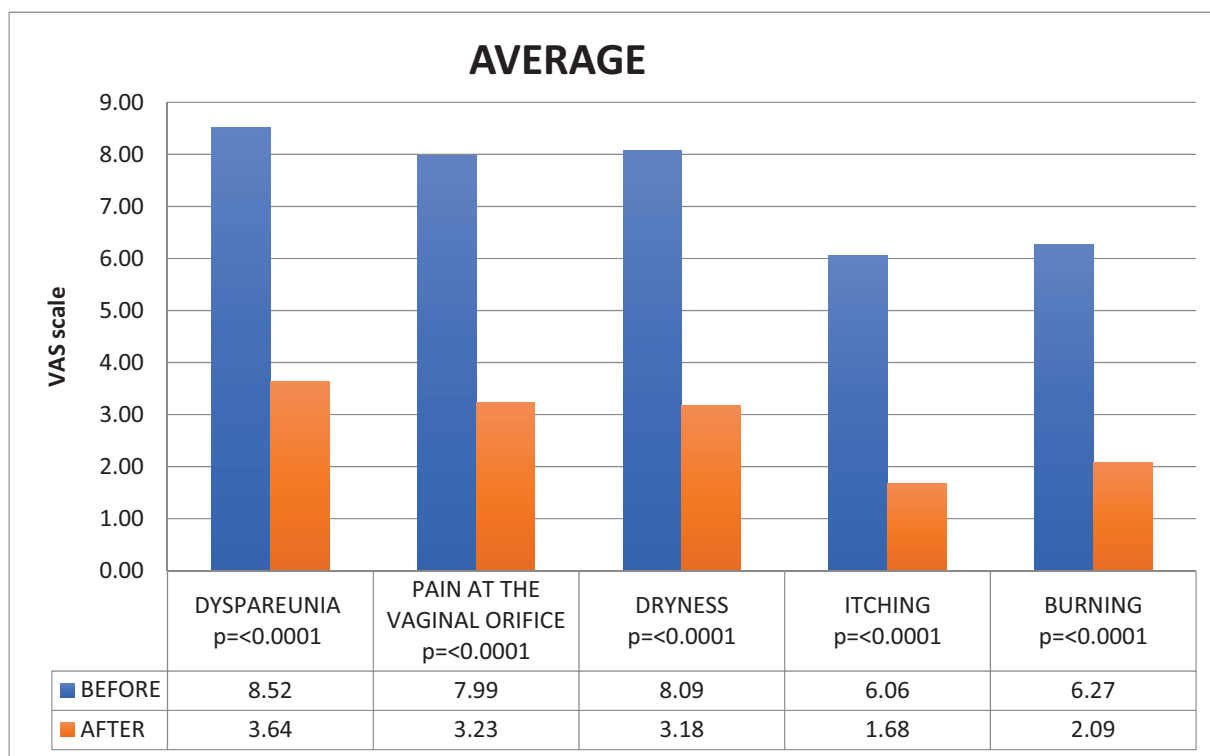
FRACTIONAL CO₂ LASER TREATMENT IN MENOPAUSE

FIG. 3. The average VAS symptoms before (in blue) and after (in red) four laser treatments. VAS was considered before the first laser treatment session and 1 month after the last laser treatment session. (Dryness: before = 8.09; after = 3.18 [$P < 0.0001$]). Dyspareunia: before = 8.52; after = 3.64 [$P < 0.0001$]. Burning: before = 6.27; after = 2.09 [$P < 0.0001$]. Vaginal orifice pain: before = 7.99; after = 3.23 [$P < 0.0001$]. Itching: before = 6.06; after = 1.68 [$P < 0.0001$]). VAS, Visual Analog Scale.

vaginal orifice (11%), and recurrent bleeding.² Vaginal atrophy may worsen over time and reduce the quality of life. In fact, 75% of women report a significant reduction in the quality of everyday life,^{2,3} increased social isolation (13%), loss of self-esteem (26%), and more difficulty with partner intimacy (40%).³

The therapeutic options for VVA include nonhormonal local therapies (ie, lubricants, moisturizers) or hormonal ones (ie, low-dose vaginal estrogen) that can be used together or alternately.⁵ Currently, local administration of estrogen is the gold standard: it is recommended in women mainly with vaginal symptoms.³³ The side effects are due to systemic adsorption of estrogen.³⁴ However, some women cannot use HT because they have hormone-dependent cancer or do not want to use estrogen or have not shown improvement with prior HT. For these women laser therapy is a new nonhormonal, nonsurgical option for the prevention and management of VVA.

In 2001 Tschanz et al²⁷ found, and were the first to publish, improvement of vulvodynia in three women treated with three CO₂ laser sessions for condylomas. In 2014 Salvatore et al²⁵ performed a prospective ex vivo study in which they used redundant vaginal edge after pelvic organ prolapse surgical operation. The use of biopsy was the strength of this study because it attested to the improvement, but the sample size was too small. In 2014 Zerbinati et al³¹ conducted a histological study in 50 women: they found an improvement of

vaginal tropism both with the optical microscope and the electron microscope (increase of collagen, glycogen, proliferating cells, blood vessels, fibroblasts). In 2018 Eder²⁸ analyzed biopsies from 40 women and confirmed the increase of collagen and wall thickness.

In 2015 Perino et al¹⁰ conducted a prospective study in 48 women: they demonstrated a significant reduction of symptoms ($P < 0.0001$) and overall satisfaction in the women (91.7%). In 2015 Biglia et al,³⁵ in 2016 Pieralli et al,²⁴ and Pagano et al,²¹ and in 2017 Santen et al³⁶ performed studies on breast cancer survivors who could not use HT; they found a strong improvement in their quality of life.

In the literature there are 22¹⁰⁻³¹ articles about laser therapy, 17 of them (77.27%)^{10,11,17-30,32} regarding the CO₂ laser. These include 1 case report,²⁷ 1 retrospective study,²¹ and 15 prospective studies.^{10,17-20,22-26,28-32} Our study is the first retrospective multicenter study on fractional CO₂ laser treatment of VVA in a large sample size. Our study examined 645 women; thus, it greatly exceeds previous studies that examined an average of 53.8 women – minimum 3,²⁷ maximum 184.¹⁸ In our study we used the VAS and pH scale because we had to be consistent and select the same parameters for all the samples (1,213 women) and throughout all four sites.

Previously, eight studies^{10,19,20,23,24,26,28,29} used the VAS and the Vaginal Health Index (VHI), one³² only the VAS, two^{22,31} the VHI. Moreover only three studies^{20,22,29} analyzed

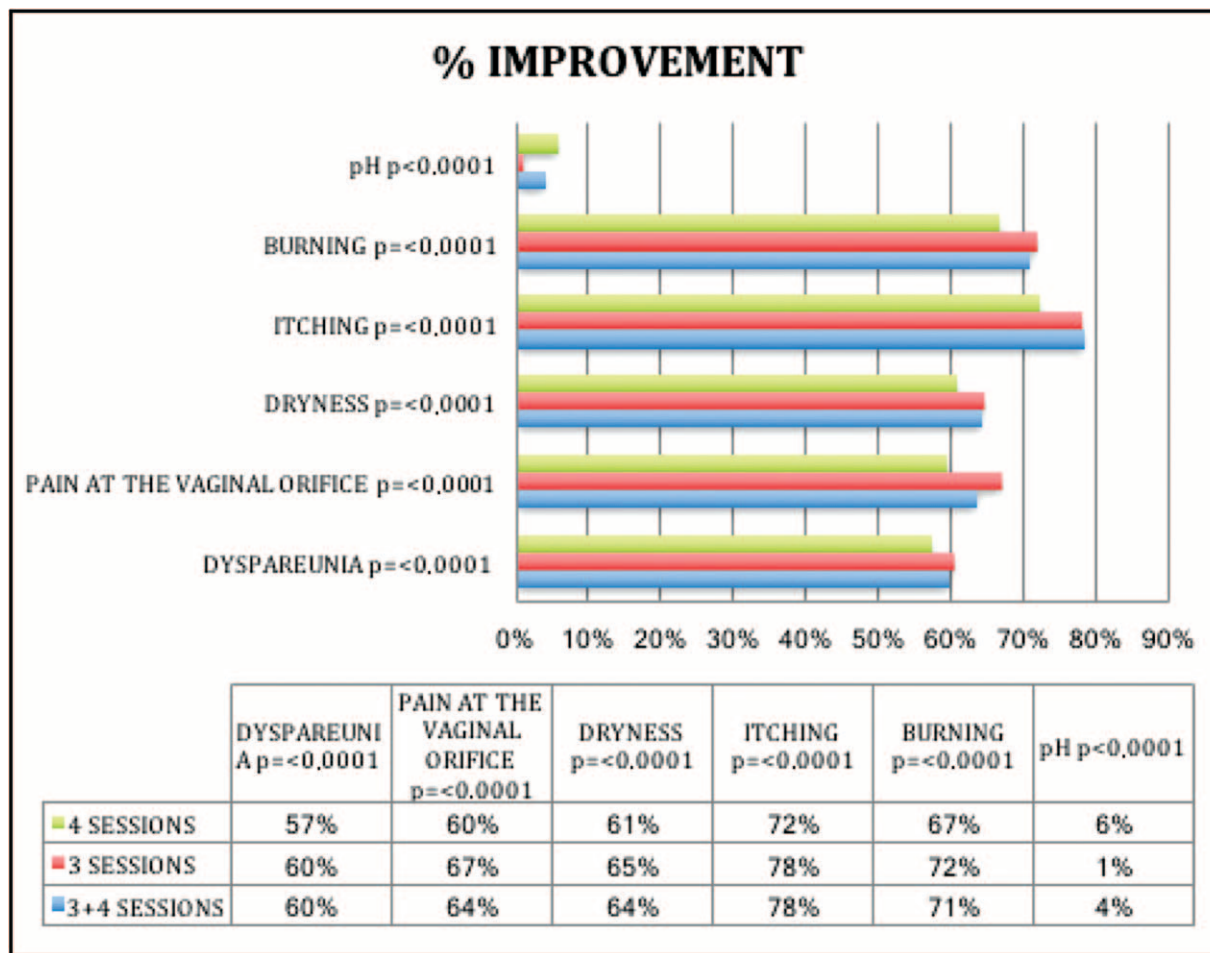


FIG. 4. The Improvement percentage of each subgroup (only 3 sessions in red, only 4 sessions in green and 3 + 4 sessions in blue) and by each symptom considered. The improvement was evaluated by assessing the between pre- and postlaser treatment by VAS, then a mathematical proportion for the percentage was applied.

the pH scale. In both of our studies and those of others, a significant improvement was noticed. Comparing the data in this study with some of the other existing studies, it might appear that improvement of atrophy and dyspareunia was slightly lower, 64% versus 68% and 60% versus 70%, respectively. However, if the delta is examined, the same results are obtained as in prior published studies, 5.33 versus 5.33 and 5.19 versus 5.15, respectively. This difference may be due to our larger sample size. Moreover, in our study the decrease in itching and burning was slightly greater than that of other studies, 75% versus 78% and 71% versus 68%, respectively.

The improvement in vaginal orifice pain was 64% in our study and cannot be compared with previous studies since we were the first to do so. Our research is one of the few studies that examined changes in pH and has found a meaningful improvement between the pre- and post-treatment (5.82 vs 5.61). No improvement was found in one study²² (pH pre-treatment 5.5; pH post-treatment 5.65), whereas in another study³⁷ a 1.5 VHS improvement of the pH was reported.

In our study, as with most of the published studies, adverse events related to the procedure have not been reported. The

CO₂ laser procedure is effective at reducing significantly ($P < 0.0001$) all symptoms related to VVA (dryness, dyspareunia, burning, and itching) and vaginal pH ($P < 0.0001$) which gets back to the physiological value.

The strengths of our study are the large sample size (645 women enrolled) and the fact of being a multicenter study. The limitations of our study are being a retrospective study in comparison with prospective or randomized studies, the different follow-up of the four sites, the lack of biopsies and the lack of a control group. Other prospective and randomized studies with extended follow-up are necessary to validate the effectiveness of the CO₂ laser.

CONCLUSIONS

Fractional CO₂ laser has been proven to be a valid and effective therapeutic option that may be used simultaneously or alternately with the other possible therapies in patients suffering from GSM, particularly in patients suffering from VVA symptoms. Fractional CO₂ laser seems to be a safe treatment (no side effects were observed), and an easily reproducible treatment tool in an outpatient setting. It is a treatment that leads to improved quality of life for women.

FRACTIONAL CO₂ LASER TREATMENT IN MENOPAUSE

Our results show the effectiveness and the successful tolerance of the CO₂ laser system on GSM symptoms.

Acknowledgments: The authors thank the collaborators of LARA group (LAser Regeneration Advanced).

REFERENCES

- Mac Bride MB, Rhodes DJ, Shuster LT. Vulvovaginal atrophy. *Mayo Clin Proc* 2010;85:87-94.
- Nappi RE, Kokot-Kierepa M. Vaginal health: insights, views & attitudes (VIVA) - results from an international survey. *Climacteric* 2012;15:36-44.
- Nappi RE, Lachowsky M. Menopause and sexuality: prevalence of symptoms and impact on quality of life. *Maturitas* 2009;63:138-141.
- Nappi RE, Kokot-Kierepa M. Women's voices in menopause: results from an international survey on vaginal atrophy. *Maturitas* 2010;67:233-238.
- Gandhi J, Chen A, Dagur G, et al. Genitourinary syndrome of menopause: an overview of clinical manifestations, pathophysiology, etiology, evaluation, and management. *Am J Obstet Gynecol* 2016;215:704-711.
- Sturdee DW, Panay N. International Menopause Society Writing Group. Recommendations for the management of postmenopausal vaginal atrophy. *Climacteric* 2010;13:509-522.
- Bygdeman M, Swahn ML. Replens versus dienoestrol cream in the symptomatic treatment of vaginal atrophy in postmenopausal women. *Maturitas* 1996;23:259-263.
- Biglia N, Peano E, Sgandurra P, et al. Low-dose vaginal estrogen or vaginal moisturizer in breast cancer survivors with urogenital atrophy: a preliminary study. *Gynecol Endocrinol* 2010;26:404-412.
- Santen RJ. Vaginal administration of estradiol: effects of dose, preparation and timing on plasma estradiol levels. *Climacteric* 2015;18:121-134.
- Perino A, Calligaro A, Forlani F, et al. Vulvo-vaginal atrophy: a new treatment modality using thermo-ablative fractional CO₂ laser. *Maturitas* 2015;80:296-301.
- Salvatore S, Athanasiou S, Candiani M. The use of pulsed CO₂ lasers for the treatment of vulvovaginal atrophy. *Curr Opin Obstet Gynecol* 2015;27:504-508.
- Gambacciani M, Torelli MG, Martella L, et al. Rationale and design of the Vaginal Erbium Laser Academy Study (VELAS): an international multicenter observational study on genitourinary syndrome of menopause and stress urinary incontinence. *Climacteric* 2015;18 (suppl 1):43-48.
- Gambacciani M, Levancini M, Cervigni M. Vaginal erbium laser: second-generation thermotherapy for the genitourinary syndrome of menopause. *Climacteric* 2015;18:757-763.
- Gaspar A, Brandi H, Gomez V, Luque D. Efficacy of Erbium: YAG laser treatment compared to topical estriol treatment for symptoms of genitourinary syndrome of menopause. *Lasers Surg Med* 2017;49:160-168.
- Lapji GA, Yakovleva AY, Neimark AI. Structural reorganization of the vaginal mucosa in stress urinary incontinence under conditions of Er:YAG laser treatment. *Bull Exp Biol Med* 2017;162:510-514.
- Kamilos MF, Borrelli CL. New therapeutic option in genitourinary syndrome of menopause: pilot study using microablative fractional radiofrequency. *Einstein (Sao Paulo)* 2017;15:445-451.
- Athanasiou S, Pitsouni E, Falagas ME, Salvatore S, Grigoriadis T. CO₂-laser for genitourinary syndrome of menopause. How many laser sessions? *Maturitas* 2017;104:24-28.
- Pieralli A, Bianchi C, Longinotti M, et al. Long-term reliability of fractioned CO₂ laser as a treatment for vulvovaginal atrophy (VVA) symptoms. *Arch Gynecol Obstet* 2017;296:973-978.
- Siliquini GP, Tuninetti V, Bounous VE, Bert F, Biglia N. Fractional CO₂ laser therapy: a new challenge for vulvovaginal atrophy in postmenopausal women. *Climacteric* 2017;20:379-384.
- Pitsouni E, Grigoriadis T, Tsiveleka A, Zacharakis D, Salvatore S, Athanasiou S. Microablative fractional CO₂-laser therapy and genitourinary syndrome of menopause: an observational study. *Maturitas* 2016;94:131-136.
- Pagano T, De Rosa P, Vallone R, et al. Fractional microablative CO₂ laser for vulvovaginal atrophy in women treated with chemotherapy and/or hormone therapy for breast cancer: a retrospective study. *Menopause* 2016;23:1108-1113.
- Sokol ER, Karram MM. An assessment of the safety and efficacy of a fractional CO₂ laser system for the treatment of vulvovaginal atrophy. *Menopause* 2016;23:1102-1107.
- Perino A, Cucinella G, Gugliotta G, et al. Is vaginal fractional CO₂ laser treatment effective in improving overactive bladder symptoms in postmenopausal women? Preliminary results. *Eur Rev Med Pharmacol Sci* 2016;20:2491-2497.
- Pieralli A, Fallani MG, Becorpi A, et al. Fractional CO₂ laser for vulvovaginal atrophy (VVA) dyspareunia relief in breast cancer survivors. *Arch Gynecol Obstet* 2016;294:841-846.
- Salvatore S, Leone Roberti Maggiore U, Athanasiou S, et al. Histological study on the effects of microablative fractional CO₂ laser on atrophic vaginal tissue: an ex vivo study. *Menopause* 2015;22:845-849.
- Salvatore S, Nappi RE, Zerbinati N, et al. A 12-week treatment with fractional CO₂ laser for vulvovaginal atrophy: a pilot study. *Climacteric* 2014;17:363-369.
- Tschanz C, Salomon D, Skaria A, Masouyé I, Vecchietti GL, Harms M. Vulvodinia after CO₂ laser treatment of the female genital mucosa. *Dermatology (Basel)* 2001;202:371-372.
- Eder SE. Early effect of fractional CO₂ laser treatment in postmenopausal women with vaginal atrophy. *Laser Ther* 2018;27:41-47.
- Samuels JB, Garcia MA. Treatment to external labia and vaginal canal with CO₂ laser for symptoms of vulvovaginal atrophy in postmenopausal women. *Aesthet Surg J* 2019;39:83-93.
- Behnia-Willison F, Sarraf S, Miller J, et al. Safety and long-term efficacy of fractional CO₂ laser treatment in women suffering from genitourinary syndrome of menopause. *Eur J Obstet Gynecol Reprod Biol* 2017;213:39-44.
- Zerbinati N, Serati M, Origoni M, et al. Microscopic and ultrastructural modifications of postmenopausal atrophic vaginal mucosa after fractional carbon dioxide laser treatment. *Lasers Med Sci* 2015;30:429-436.
- Salvatore S, Nappi RE, Parma M, et al. Sexual function after fractional microablative CO₂ laser in women with vulvovaginal atrophy. *Climacteric* 2015;18:219-225.
- Leiblum S, Bachmann G, Kemmann E, Colburn D, Swartzman L. Vaginal atrophy in the postmenopausal woman. The importance of sexual activity and hormones. *JAMA* 1983;249:2195-2198.
- Santen RJ, Pinkerton JV, Conaway M, et al. Treatment of urogenital atrophy with low-dose estradiol: preliminary results. *Menopause* 2002;9:179-187.
- Biglia N, Bounous VE, Sgro LG, D'Alonzo M, Pecchio S, Nappi RE. Genitourinary syndrome of menopause in breast cancer survivors: are we facing new and safe hopes? *Clin Breast Cancer* 2015;15:413-420.
- Santen RJ, Stuenkel CA, Davis SR, Pinkerton JV, Gompel A, Lumsden MA. Managing menopausal symptoms and associated clinical issues in breast cancer survivors. *J Clin Endocrinol Metab* 2017;102:3647-3661.
- Pitsouni E, Grigoriadis T, Falagas ME, Salvatore S, Athanasiou S. Laser therapy for the genitourinary syndrome of menopause. A systematic review and meta-analysis. *Maturitas* 2017;103:78-88.