

Postpartum perineal pain: may the vaginal treatment with CO₂ laser play a key-role in this challenging issue?

Maurizio Filippini, Miriam Farinelli, Salvatore Lopez, Carla Ettore, Ferdinando Antonio Gulino & Stella Capriglione

To cite this article: Maurizio Filippini, Miriam Farinelli, Salvatore Lopez, Carla Ettore, Ferdinando Antonio Gulino & Stella Capriglione (2019): Postpartum perineal pain: may the vaginal treatment with CO₂ laser play a key-role in this challenging issue?, The Journal of Maternal-Fetal & Neonatal Medicine, DOI: [10.1080/14767058.2019.1628208](https://doi.org/10.1080/14767058.2019.1628208)

To link to this article: <https://doi.org/10.1080/14767058.2019.1628208>



Accepted author version posted online: 04 Jun 2019.
Published online: 17 Jun 2019.



Submit your article to this journal [↗](#)



View Crossmark data [↗](#)

Postpartum perineal pain: may the vaginal treatment with CO₂ laser play a key-role in this challenging issue?

Maurizio Filippini^a, Miriam Farinelli^a, Salvatore Lopez^{b,c}, Carla Ettore^d, Ferdinando Antonio Gulino^d and Stella Capriglione^a

^aDepartment of Obstetrics and Gynecology, Hospital State of Republic of San Marino, San Marino, Republic of San Marino;

^bDepartment of Obstetrics, Gynecology, and Reproductive Sciences, Yale University School of Medicine, New Haven, CT, USA;

^cDepartment of Experimental and Clinical Medicine, Magna Graecia University, Catanzaro, Italy; ^dDipartimento Materno-Infantile, ARNAS Garibaldi-Nesima, Catania, Italy

ABSTRACT

Purpose: Pregnancy and childbirth, despite being physiological events, represent a very delicate period in a woman's life, because they expose to important vulvo-perineal traumas. The pelvic pain that follows each delivery, whether spontaneous or surgical (caesarean section), does not end in the first days after birth but, depending on the studies, becomes persistent in a very variable percentage of cases. Therefore, in the present pilot study, we aimed, for the first time in literature, to assess the efficacy of CO₂ laser in women affected by perineal postpartum symptoms.

Materials and methods: Between February 2013 and June 2018, all women with late postpartum pelvic pain referred to the Department of Obstetrics and Gynecology of San Marino Hospital, were recruited and treated using the CO₂ laser for three applications every 4–6 weeks.

Results: Between February 2013 and June 2018, according to the inclusion and exclusion criteria, 32 women with late postpartum pelvic pain were recruited in our protocol study. Mean age of patients was 34.1 years. At latest follow-up, our data demonstrated an improvement in symptoms (dyspareunia, pain at introitus, vaginal dryness, itching and vaginal burning) with a mean reduction of this symptom of 70% from baseline.

Conclusions: This study has shown the effectiveness of CO₂ laser treatment in postpartum perineal pain. Nevertheless, our results should be considered promising but preliminary. In fact, they need to be tested in larger cohort of patients to confirm its application in clinical practice and to evaluate the long-term duration of this treatment.

ARTICLE HISTORY

Received 17 January 2019

Accepted 2 June 2019

KEYWORDS

CO₂ laser; dyspareunia; postpartum pelvic pain; perineal pain; obstetric injuries

Introduction

Pregnancy and childbirth, despite being physiological events, represent a very delicate period in a woman's life, because they expose to important vulvo-perineal traumas. The pelvic pain that follows each delivery, whether spontaneous or surgical (caesarean section), does not end in the first days after birth but, depending on the studies, becomes persistent in a very variable percentage of cases. This pain can last even months, causing significant problems for women who often have to undergo to long procedures before arriving at a correct diagnosis and consequently a targeted therapy.

In fact, many clinical studies have shown that pregnancy and the birth of a child define a temporal window highly exposed to female sexual dysfunction, of which the most frequent is vulvar pain.

The International Society for the Study of Vulvovaginal Diseases (ISSVD) defines the vaginal vestibule (80% of cases) as the site where the burning and postpartum pain is concentrated: in these cases we speak of provoked vestibulodynia (VP) or vulvar vestibulitis (VV).

Postpartum pain occurs under various manifestations, but the most important connotations involve mainly the introital dyspareunia (sometimes even the deep area), the vulvar pain and the chronic pelvic pain. Prevalence studies indicate that postpartum pain is one of the worst results in the first day after childbirth and that it may be present in 88% of the women who have recently given birth [1,2]. A report from a Chinese study suggests that one of the major long-term concerns is continuous pain in the perineal region after a vaginal birth [3]. In fact, the

spontaneous postpartum pelvic pain can be present in a high percentage of women, with an incidence ranging up to 18% at 3 months after birth [4]. It is estimated that 50% of women resume sexual activity 5–6 weeks after delivery and 90% after 3 months [5]. Between 41 and 67% of women report the appearance of dyspareunia, pain caused by sexual intercourse, especially in the first 2–3 months after childbirth. This dysfunction persists in 30% of cases after the first 3 months and in 20% of cases it can last up to the following 6 months. Therefore, the first postpartum 6 months are absolutely crucial for the woman's quality sexual life [6]. The postpartum vulvar pain and dyspareunia are therefore inserted in a dysfunctional biological and psycho-sexual context, which must be carefully investigated in order to allow an effective treatment and a complete resolution. Many studies have recognized the contribution of various factors that can significantly influence the emergence of postpartum sexual dysfunction. Systemic (breast-feeding, anemia, depression, poor quality of sleep, obesity), genital (episiotomy or spontaneous perineal lacerations), psychosexual and relational (decreased sexual impulse, decreased central pleasure, decreased sense of sexual attraction fear of experiencing further pain, transition from couple to parents) factors were called into question, which trigger, either alone or combined, a negative feedback circle that impacts on female and couple sexual life, even if the vulvo-perineal trauma remains the first step into the genesis of postpartum dyspareunia and partly into the genesis of chronic pelvic pain [5]. This is because in the vaginal vestibule there is a dense branching of free terminations of the pudendal nerve, much more than in vagina, and those nociceptors are immediately below the mucosa, creating a network of sensory neuronal networks ready to transmit the sensory stimuli to the spinal cord, leading sometimes to a neuropathic pain syndrome at multifactorial genesis. Thus, many effective alternatives designed to minimize this complaint have been studied. Some of the therapies used to provide perineal analgesia following vaginal deliveries include pharmacological and nonpharmacological interventions.

The use of nonpharmacological treatments to manage postpartum perineal pain has been investigated worldwide, because, in addition to being associated with lower risks of adverse reactions, they lower the costs associated with medications [7]. Hence, analgesic therapy involving perineal cryotherapy is being widely researched, because it is easily accessible and inexpensive [8–13].

Applying cold therapy immediately after acute injuries reduces inflammation, secondary hypoxia, the production of cellular debris, edema, hematoma development, the metabolism, spasticity, muscle spindle

activity, and nerve transmissions. Moreover, it increases the release of endorphins and stimulates the repair process [14–17].

Cryotherapy reduces blood flow and the metabolism within the affected region, thereby limiting edema formation. This favors the lymphatic drainage of the site, because there is less pressure in the extracellular fluid. All of these factors reduce nerve stimulation within the affected region and, therefore, pain [18].

Among the nonpharmacological treatments, there are those who aimed to reduce painful trigger points (relaxation exercises, internal and external vaginal massage, bioelectromyographic feedback), those linked to block peripheral sensitization, especially when vestibular hypersensitivity is very localized, with prevalent scar component of vulvo-vestibular nerve endings (submucosal cortisone or anesthetic injection, submucosal botulinum toxin type A infiltration), or central (physical stimulation of transcutaneous electrical nerve – TENS –, use of palmitoylethanolamide – PEA) or those linked to the reduction of muscular hypertonus, often present in case of perineal pain (pelvic floor rehabilitation exercises, vaginal diazepam). Also the use of heat has beneficial effects on the tissues. In fact, temperatures above 40°C (104°F) block the cellular chemical messengers, responsible to alarm the body about the pain, with an effect that can last up to one hour, reducing inflammation and alleviating the symptom.

On the basis of these assumptions, it came out the idea to apply the thermal energy produced by CO₂ laser light into tissues, in an attempt to exploit the typical characteristics of this important therapeutic source. The action of microremodeling of superficial nociceptive terminations, together with the stimulating action on the dermal–epidermal trophism, leading to epithelium thickening with papilla lengthening and to fibroblastic and connective tissue matrix stimulation, is the main characteristic at the base of the rationale about the use of CO₂ laser in the treatment of postpartum sexual dysfunction. In the previous 30 years, CO₂ laser has become the gold standard treatment in dermatologic surgery for the treatment of a large number of skin and mucosal lesions. Considering the increasing demands regarding esthetic treatment, laser technology has been successfully used in the past 10 years to treat esthetical diseases such as acne scars, and to improve photo and chrono-aging facial effects [19].

The introduction of the fractional microablative technology represented an integration to the ablative resurfacing technique, reducing healing time and side

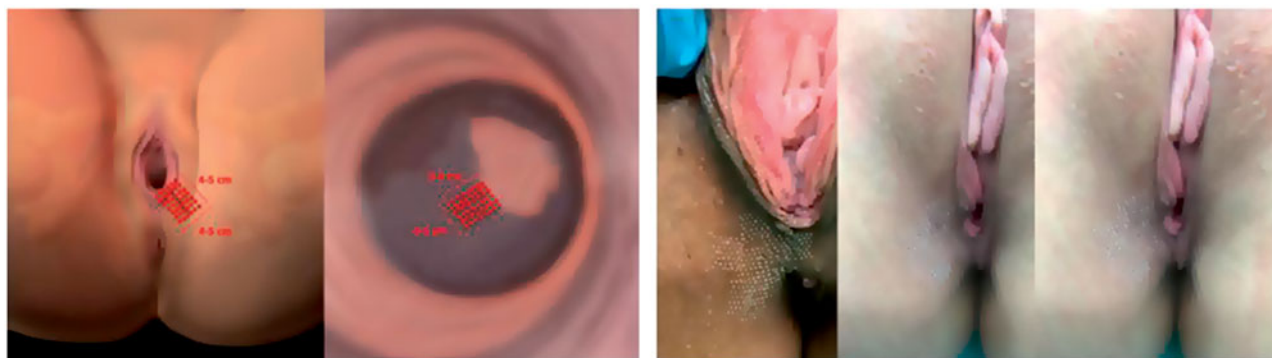


Figure 1. The perineal area treated with CO₂ laser.

effects. Technological research gives us the possibility to choose from various kinds of pulses with different ablation and coagulation characteristics, with consequent faster healing, no scarring, and the stimulation of new collagen production. Due to the effects on tissues rejuvenation, many studies have been carried out since 2008 on the application of CO₂ laser treatment on vaginal tissue, demonstrating the benefits of this technology in reduction of vulvo-vaginal atrophy (VVA) [20].

Therefore, in the present pilot study, we aimed, for the first time in literature, to assess the efficacy of CO₂ laser in women affected by perineal postpartum symptoms.

Materials and methods

Between February 2013 and June 2018, all women with late postpartum pelvic pain referred to the Department of Obstetrics and Gynecology of San Marino Hospital, were recruited in this descriptive pilot study and treated using the CO₂ laser (SmartXide2V2LR, MonaLisa Touch, Deka M.e.l.a, Firenze, Italy). The inclusion criteria were as follows: (1) age > 18 years; (2) pelvic pain after >6 months postpartum; (3) informed consent; (4) Pap test and vaginal swab negative, performed 2 weeks before the treatment. Exclusion criteria were: (1) a history of self-injurious behavior; (2) a history of clinical diagnosis or treatment of any psychiatric disorder; (3) daily anti-epileptic medication. The protocol was approved by the Internal Review Board. An accurate anamnesis was recorded for all patients, including parity, maternal age, type of delivery, degree of perineal trauma among vaginal deliveries, type of cesarean delivery, type of anesthesia for cesarean delivery. The postpartum pelvic pain was evaluated, using the Visual Analogue Scale (VAS), consisting of a straight line with the endpoints defining extreme limits such as “no

pain at all” (0) and “pain as bad as it could be” [10]. Patient is asked to mark her pain level on the line between the two endpoints. The protocol with MonaLisa Touch consisted of three applications every 4–6 weeks. The CO₂ laser (SmartXide2V2LR, MonaLisa Touch, Deka, Florence, Italy) has been set with a DOT power of 30 W (microablative), a scan time of 1000 μs, a DOT spacing of 1000 μm and a depth (Stack) of 1. Regarding the laser treatment, the laser pulse beam is first applied by means of a 0° probe on the external perineal area, for a length and depth of 4–5 cm, along the perineal skin scar and then the 90° probe is inserted into the vagina, without speculum and without using lubricants or topical anesthetics, along an area of 4–5 cm of perineal skin scar (Figure 1).

The present analysis focused on changes in pelvic pain, assessed at baseline, after 4, 8, 12, and 16 weeks. All analyses were done on an intention-to-treat basis. Comparisons between treatment groups were conducted using the Wilcoxon rank-sum test for continuous measures and Fisher’s exact test for categorical measures.

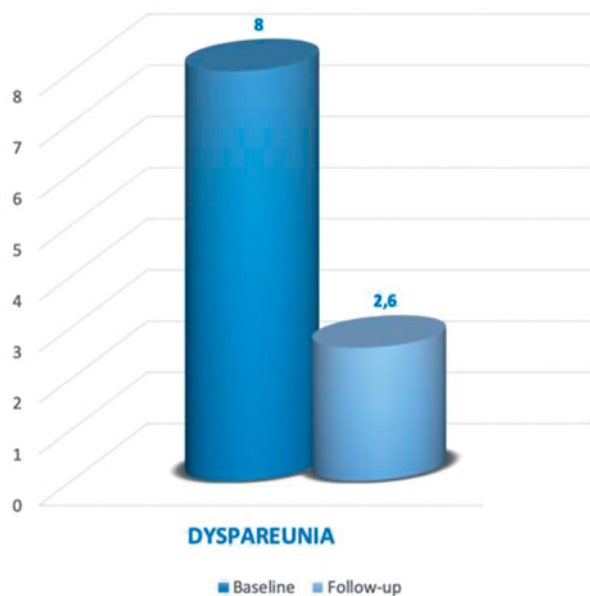
Results

Between February 2013 and June 2018, according to the inclusion and exclusion criteria, 32 women with late postpartum pelvic pain referred to the Department of Obstetrics and Gynecology of San Marino Hospital, were recruited in our protocol study. Mean age of patients was 34.1 years. Mean parity was 1.1. All patients’ characteristics are reported in Table 1.

Gynecological evaluation was performed before treatment to assess the level of atrophy and subjective symptoms, to exclude prolapse of the pelvic organs that cannot be greater than the second degree, to rule out infections, and to perform a Pap test, which must be negative. All patients had a pH between 5

Table 1. Patients' characteristics.

	Study group
Number of patients	32
Age (mean \pm DS)	34.1 \pm 6.1
Parity (mean \pm DS)	1.6 \pm 2.2
Vaginal delivery (n, %)	28/32, 87.5%
Operative delivery (n, %)	5/28, 17.8%
Perineal lacerations	I degree 15%
	II degree 80%
	III degree 5%
Cesarean delivery (n, %)	4/32, 12.5%
Treatment session (mean)	2.4

**Figure 2.** Dyspareunia at baseline and at the end of treatment.

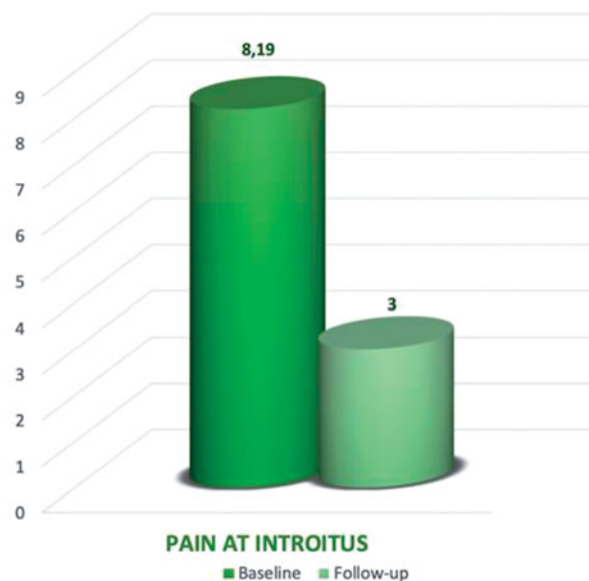
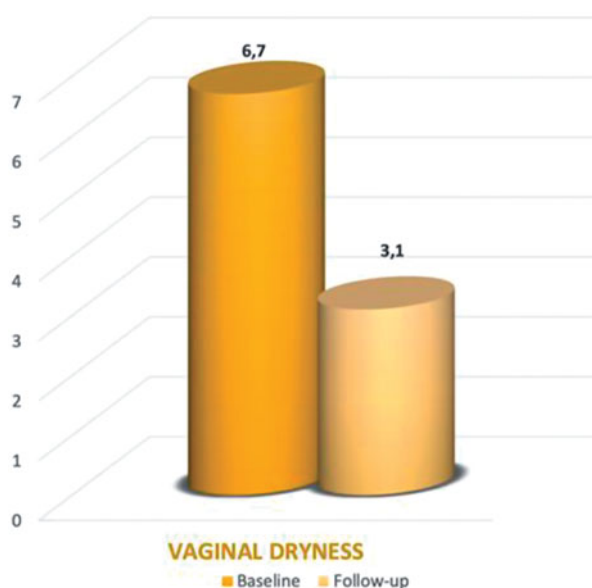
and 7 and vaginal swab performed 2 weeks before the treatment resulted negative.

In our study group, 28/32 (87.5%) had a vaginal delivery, in 5/28 cases (17.8%) it was an operative delivery. 4/32 (12.5%) underwent to a cesarean section. Perineal lacerations were classified of I degree in 15% of cases, II degree in 80% of cases, and III degree in 5% of cases.

The compliance of patients with the treatment was high, meanly all patients underwent to 2.4 treatment sessions. At the latest follow-up, our data demonstrated an improvement in dyspareunia with a mean reduction of this symptom of 67.5% from baseline. In fact, at time 0 the mean VAS for dyspareunia was 8, while at latest follow up was 2.6 (Figure 2).

Concerning the pain at introitus, our results demonstrated a mean reduction of this symptom of 63.3%. In fact, at time 0 the mean VAS for the pain at introitus was 8.19, while at latest follow up was 3 (Figure 3).

Concerning the vaginal dryness, our results demonstrated a mean reduction of this symptom of 53.7%. In

**Figure 3.** Pain at introitus at baseline and at the end of treatment.**Figure 4.** Vaginal dryness at baseline and at the end of treatment.

fact, at time 0 the mean VAS for the vaginal dryness was 6.7, while at latest follow up was 3.1 (Figure 4).

Concerning the itching, our results demonstrated a mean reduction of this symptom of 58%. In fact, at time 0 the mean VAS for itching was 5, while at latest follow up was 2.1 (Figure 5).

Concerning the vaginal burning sensation, our results demonstrated a mean reduction of this symptom of 75.8%. In fact, at time 0 the mean VAS for vaginal burning sensation was 5.8, while at latest follow up was 1.4 (Figure 6).

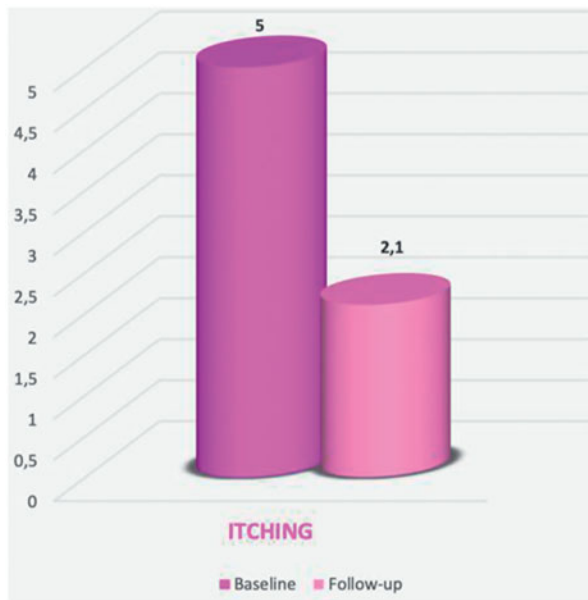


Figure 5. Itching at baseline and at the end of treatment.

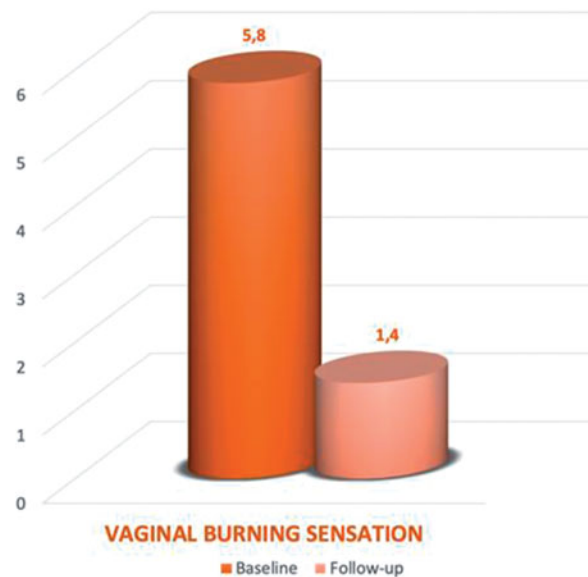


Figure 6. Vaginal burning at baseline and at the end of treatment.

All these results are summarized in Table 2. These results were reported at least after 2 months after the end of treatment.

Discussion

Three are the most involved mechanisms in the genesis of post-partum pain:

1. hypoestrogenism resulting from breastfeeding;
2. the involvement of nerve endings in the perineal scar;

3. activation of nociceptors on a neuroinflammatory basis (mast cell activation).

These mechanisms may be present in isolation or overlap in a synergistic process that accentuates perineal pain. Regarding the first aspect, a predominant role is played by hormonal changes. After delivery, the ovary is subject to a sort of “silencing”, characterized by minimal levels of estradiol, progesterone, and testosterone, but by high levels of prolactin, which appear higher in women who breastfeed. Clinical studies show that breastfeeding women more frequently exhibit dyspareunia 6 months after delivery than women who use artificial feeding [21].

This is due to the hypo-atrophy, and therefore to the vaginal dryness, induced by the high blood levels of prolactin, which suppresses the production of gonadotropins resulting in hypoestrogenism, a situation very similar to what happens in postmenopause (mucosal thinning, pallor, accentuated vascularization, reduced lubrication).

In patients with dyspareunia and vulvar pain, mucosal thinning makes the superficial nerve endings amplify the nociception.

Estrogens tend to play a role in the protection of nerve endings and in the pain development of peripheral nociceptors, and there is an inverse proportionality between estrogen level, vestibular pain, and hypersensitivity of nerve endings.

In addition, women with dyspareunia and postpartum vestibulodynia show higher chronic neuroinflammation markers (lymphocytic and mast cell infiltrates) [22,23].

On the basis of the data reported in literature, CO₂ laser light has proved to be useful for the treatment of vulvo-vaginal epithelium.

The mechanism of these changes has been widely demonstrated by numerous studies [24].

The vaginal epithelium is characterized by the absence of keratin and the presence of a high water content. Tissue damage caused by the microablations and heating of the CO₂ laser stimulates fibrocytes to return to being productive fibroblasts that can restore the correct composition of collagen fibers within the amorphous substance with adequate water content. The effects of the fractional CO₂ laser on the mucosa can be summarized in a central zone of vaporization, an intermediate zone characterized by denaturation and contraction of the collagen fibers, which creates a thermal barrier for the underlying mucosa, and a peripheral zone of hyperthermia.

In this latter area, the heat activates the heat shock proteins, in particular HSP 43-47-70. These proteins

Table 2. Symptom reduction at baseline and after the end of treatments.

	Baseline	After the end of treatments	% of reduction
Dyspareunia	8	2.6	−67.5%
Pain at introitus	8.19	3	−63.3%
Vaginal dryness	6.7	3.1	−53.7%
Itching	5	2.1	−58%
Vaginal burning sensation	5.8	1.4	−75.8%

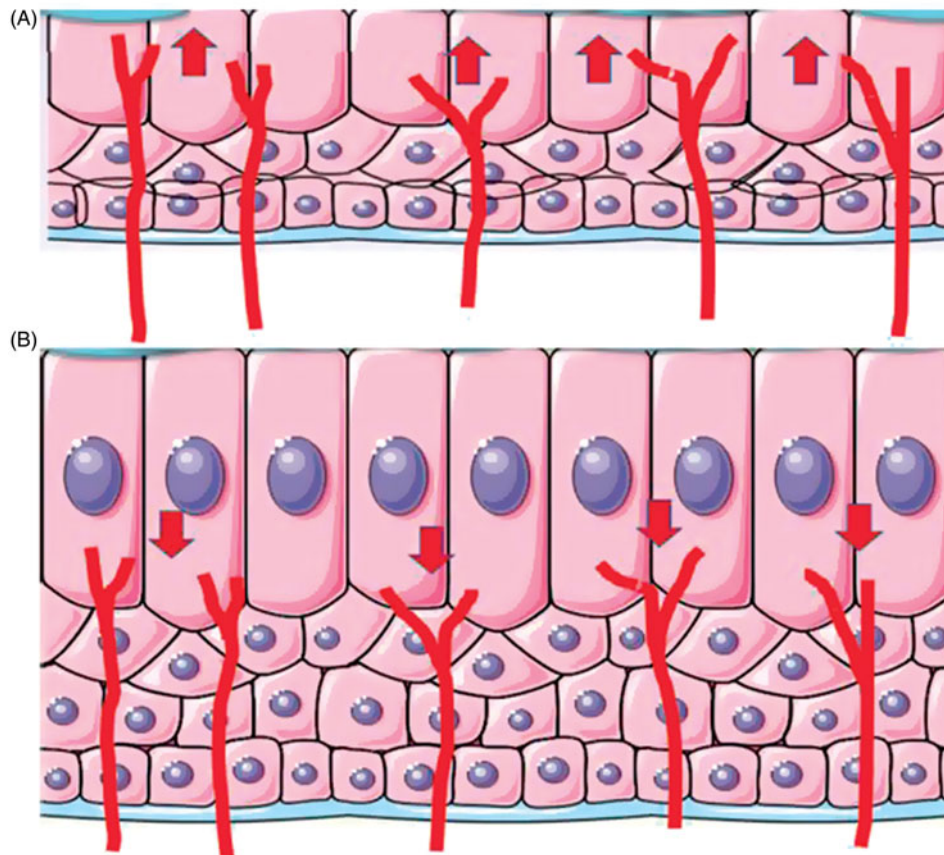


Figure 7. “Coming back” mechanism: (A) The atrophic action linked to hypoestrogenism causes a thinning of the vulvo-vaginal epithelium, making the nerve endings more superficial and consequently amplifying the nociception; (B) the fibroblastic activation and the consequent neo-collagenesis, in addition to the increase in thickness of the epithelium, lead to a lengthening of the dermal papillae with consequent dispersion and removal of the nerve endings from the surface.

induce a local increase in different cytokines: transforming growth factor-A, basic fibroblast growth factor, epidermal growth factor, platelet-derived growth factor and vascular endothelial growth factor, stimulating matrix proteins such as collagen, angiogenic activity with endothelial cell migration and proliferation, re-epithelization, regulating neoangiogenesis, and activating fibroblasts to produce new collagen and other components of the extracellular matrix. Using a polarized light, a layer of small collagen fibers generated by the denatured collagen can be highlighted. So, the laser also works at depth without causing irreversible damage. In fact, the fibers are of small caliber and intact [25]. The final effect is to restore the correct permeability to the connective tissue. The increase in nutrients that reach the mucosa

improves vaginal wall turgor; the hydration reduces itching and burning, increasing vaginal transudate that decreases dryness and dyspareunia and the recovery of mucosa tropism, with an increase of intracellular glycogen, leading to colonization by lactobacilli and a decrease in vaginal pH.

Therefore, the rationale for the use of CO₂ laser for pelvic postpartum pain is probably due to a “coming back” mechanism, through which the fibroblastic activation and the consequent neocollagenesis, lead to a lengthening of the dermal papillae with consequent dispersion and removal of the nerve endings from the vestibular surface, making the thin nociceptive nerve fibers less superficial and rich in the vulvar gain and vestibule (Figure 7).

Spontaneous laceration or episiotomy can involve the subtle sensory terminations of the pudendal nerve in a scarring process. Terminations that, during the period of fetal progression, may be susceptible to stretching even 30–35% of their length, with consequent microlesions and vulvo-perineal pain [26].

Fibroconnector adhesences formed at the vulvo-perineal scar, even of slight extent, could subsequently be the site of hyperacologic nerve endings grown within the same adhesion and containing some nerve fibers with synaptophysin, peptide related to the calcitonin gene and p-immunoreactive substance, and involved in conducting pain stimuli [6,27–30].

Finally, the fetal expulsion phase, even more if accompanied by a vulvo-vestibular trauma, can induce the activation of mast cell-mediated neuroinflammation (vestibulodynia). In fact, inflammation is the key element in the onset of neuropathic pain, especially when mediators such as nerve growth factor (NGF) and some cytokines (IL-1²) are involved in the inflammation process.

In these particular situations, the rational use of CO₂ laser seems to be due to the specific remodeling of the vaginal tissue, including the production of new collagen and other components of the extracellular matrix.

This remodeling probably leads to the debridement and release of the thin sensory nerve fibers remained trapped in the post-traumatic scar process.

For the first time in literature, in the present pilot study, we aimed to assess the efficacy of CO₂ laser in women with perineal postpartum symptoms, obtaining promising results in terms of dyspareunia, pain at introitus, vaginal dryness, itching, and vaginal burning.

The most important benefit of this treatment is that it is noninvasive and well tolerated. In fact, for the nature of the laser light, this treatment is painless, since the laser beam only penetrates a few of hundreds microns.

Nevertheless, our results should be considered promising but preliminary. In fact, they need to be tested and validated in larger cohort of patients to confirm its benefit and application in clinical practice and to evaluate the long-term duration of this treatment.

Disclosure statement

The authors declare that they have no conflict of interest.

Ethical approval

This article does not contain any studies with animals performed by any of the authors. All procedures performed in

studies involving human participants were in accordance with the ethical standards of the institutional and/or national research committee and with the 1964 Helsinki declaration and its later amendments or comparable ethical standards.

Informed consent

Informed consent was obtained from all individual participants included in the study.

References

- [1] East CE, Sherburn M, Nagle C, et al. Perineal pain following childbirth: prevalence, effects on postnatal recovery and analgesia usage. *Midwifery*. 2012;28(1):93–97.
- [2] Persico G, Vergani P, Cestaro C, et al. Assessment of postpartum perineal pain after vaginal delivery: prevalence, severity and determinants. A prospective observational study. *Minerva Ginecol*. 2013;65(6):669–678.
- [3] Li WY, Liabsuetrakul T, Stray-Pedersen B. Effect of mode of delivery on perceived risks of maternal health outcomes among expectant parents: a cohort study in Beijing, China. *BMC Pregnancy Childbirth*. 2014;14:12.
- [4] Paterson LQ, Davis SN, Khalifé S, et al. Persistent genital and pelvic pain after childbirth. *J Sex Med*. 2009;6(1):215–221.
- [5] Signorello LB, Harlow BL, Chekos AK, et al. Postpartum sexual functioning and its relationship to perineal trauma: a retrospective cohort study of primiparous women. *Am J Obstet Gynecol*. 2001;184(5):881–888.
- [6] Barrett G, Pendry E, Peacock J, et al. Women's sexual health after childbirth. *BJOG*. 2000;107(2):186–195. Murina F, Bianco V, Radici G, et al. Transcutaneous electrical nerve stimulation to treat vestibulodynia: a randomised controlled trial. *BJOG*. 2008;115(9):1165–1170.
- [7] Pitangui ACR, Sousa L, Ferreira CHJ, et al. Análise da prescrição de medidas terapêuticas para o alívio da dor em puérperas pós-episiotomia. *Rev Bras Fisioter*. 2007;11(Suppl.):80.
- [8] Lu YY, Su ML, Gau ML, et al. The efficacy of cold-gel packing for relieving episiotomy pain – a quasi-randomised control trial. *Contemp Nurse*. 2015;50(1):26–35.
- [9] Cameron H. Midwives benefit from good postnatal care, too. *Pract Midwif*. 2014;17(7):14–16.
- [10] Byrom A. Perineal pain in focus: reviewing topical anaesthetic treatments. *Pract Midwif*. 2015;18(7):24, 26–27.
- [11] Chiarelli P, Cockburn J. Postpartum perineal management and best practice. *Aust Coll Midwives Inc J*. 1999;12(1):14–18.
- [12] Bavaresco GZ, Souza RSO, Almeida B, et al. The physiotherapist as a professional to assist pregnant women. *Cien Saude Colet*. 2011;16(7):3259–3266.
- [13] Francisco AA, de Oliveira SM, Leventhal LC, et al. Cryotherapy after childbirth: the length of application

- and changes in perineal temperature. *Rev Esc Enferm USP*. 2013;47(3):555–561.
- [14] Carvalho GA, Chierichetti HSL. Avaliação da sensibilidade cutânea palmar nas aplicações de crioterapia por bolsa de gelo e bolsa de gel. *Rev Bras Ciênc Mov*. 2006;14(1):23–30.
- [15] Chesterton LS, Foster NE, Ross L. Skin temperature response to cryotherapy. *Arch Phys Med Rehabil*. 2002;83(4):543–549.
- [16] Brancaccio N, Klein AA, Böettche GA, et al. Análise de lesão muscular em ratos treinados e sedentários submetidos a crioterapia. *Fisioter Mov*. 2005;18(1):59–65.
- [17] Pastre CM, Bastos FdN, Netto Júnior J, et al. Métodos de recuperação pós-exercício: uma revisão sistemática. *Rev Bras Med Esporte*. 2009;15(2):138–144.
- [18] Swenson C, Swärd L, Karlsson J. Cryotherapy in sports medicine. *Scand J Med Sci Sports*. 1996;6(4):193–200.
- [19] Campolmi P, Bonan P, Cannarozzo G. *Laser e sorgenti luminose in dermatologia*. Milano: Masson; 2003. p. 17–40.
- [20] Filippini M, Del Duca E, Negosanti F, et al. Fractional CO₂ laser: from skin rejuvenation to vulvo-vaginal reshaping. *Photomed Laser Surg*. 2017;35(3):171–175.
- [21] Rowland M, Foxcroft L, Hopman WM, et al. Breastfeeding and sexuality immediately post partum. *Can Fam Physician*. 2005;51:1366–1367.
- [22] Pukall CF, Goldstein AT, Bergeron S, et al. Vulvodynia: definition, prevalence, impact, and pathophysiological factors. *J Sex Med*. 2016;13(3):291–304.
- [23] Cerciat M, Unkila M, Garcia-Segura LM, et al. Selective estrogen receptor modulators decrease the production of interleukin-6 and interferon-gamma-inducible protein-10 by astrocytes exposed to inflammatory challenge in vitro. *Glia*. 2010;58(1):93–102.
- [24] Salvatore S, Leone Roberti Maggiore U, Athanasiou S, et al. Histological study on the effects of microablative fractional CO₂ laser on atrophic vaginal tissue: an ex vivo study. *Menopause*. 2015;22(8):845–849.
- [25] Zerbinati N, Serati M, Origoni M, et al. Microscopic and ultrastructural modifications of postmenopausal atrophic vaginal mucosa after fractional carbon dioxide laser treatment. *Lasers Med Sci*. 2015;30(1):429–436.
- [26] Lien KC, Morgan DM, Delancey JO, et al. Pudendal nerve stretch during vaginal birth: a 3D computer simulation. *Am J Obstet Gynecol*. 2005;192(5):1669–1676.
- [27] Barrett G, Peacock J, Victor CR, et al. Cesarean section and postnatal sexual health. *Birth*. 2005;32(4):306–311.
- [28] Murina F, Karram M, Salvatore S, et al. Fractional CO₂ laser treatment of the vestibule for patients with vestibulodynia and genitourinary syndrome of menopause: a pilot study. *J Sex Med*. 2016;13(12):1915–1917.
- [29] Behnia-Willison F, Sarraf S, Miller J, et al. Safety and long-term efficacy of fractional CO₂ laser treatment in women suffering from genitourinary syndrome of menopause. *Eur J Obstet Gynecol Reprod Biol*. 2017; 213:39–44.
- [30] Salvatore S, Nappi RE, Zerbinati N, et al. A 12-week treatment with fractional CO₂ laser for vulvovaginal atrophy: a pilot study. *Climacteric*. 2014;17(4): 363–369.