

Fractional CO₂ Laser: From Skin Rejuvenation to Vulvo-Vaginal Reshaping

Maurizio Filippini, MD,¹ Ester Del Duca, MD,² Francesca Negosanti, MD,^{3,4} Diletta Bonciani, MD,⁵ Luca Negosanti, MD,⁶ Mario Sannino, MD,⁴ Giovanni Cannarozzo, MD,⁴ and Steven Paul Nisticò, MD^{4,7}

Abstract

Background: The CO₂ laser has become the gold standard treatment in dermatologic surgery for the treatment of a large number of skin and mucosal lesions. The introduction of the fractional micro-ablative technology represented an integration to the ablative resurfacing technique, reducing the healing time and the side effects. **Objective:** Vaginal rejuvenation performed with this technique is a minimally invasive procedure that stimulates internal tissues of the female lower genital tract to regenerate the mucosa, improving tissue trophism and restoring the correct functionality. **Methods:** In our experience, 386 menopausal women affected with vulvo-vaginal atrophy (VVA) were treated with three sessions of fractional micro-ablative CO₂ laser. **Results:** After three treatments, patients reported a complete improvement of the symptoms (59.94% dryness, 56.26% burn, sensation, 48.75% dyspareunia, 56.37% itch, 73.15% soreness, and 48.79% vaginal introitus pain). **Conclusions:** Fractional micro-ablative CO₂ laser seems to reduce symptoms related to vaginal atrophy. The beneficial effects were reported just after the first session and confirmed 12 months after the last session.

Keywords: vulvo-vaginal atrophy (VVA), genitourinary syndrome, vulvo-vaginal rejuvenation, fractional micro-ablative laser CO₂ technology

Introduction

IN THE PREVIOUS 30 years, CO₂ laser has become the gold standard treatment in dermatologic surgery for the treatment of a large number of skin and mucosal lesions. Considering the increasing demands regarding aesthetic treatment, laser technology has been successfully used in the past 10 years to treat aesthetical diseases such as acne scars, and to improve photo and chrono-aging facial effects.¹

The introduction of the fractional micro-ablative technology represented an integration to the ablative resurfacing technique, reducing healing time and side effects. Technological research gives us the possibility to choose from various kinds of pulses with different ablation and coagulation characteristics, with consequent faster healing, no scarring, and the stimulation of new collagen production.

Due to the effects on tissues rejuvenation, many studies have been carried out since 2008 on the application of CO₂

laser treatment on vaginal tissue. Vaginal rejuvenation is a quick and painless minimally invasive procedure that stimulates internal tissues of the female lower genital tract to regenerate the mucosa, improving tissue trophism and restoring the correct functionality.²

The progressive reduction in estrogen production during the climacteric causes many metabolic and tissue changes, above all in the genital tract, which is very sensitive to sex hormones.^{2,3}

In particular, vaginal walls become thinner, lose their elasticity and the typical rognation of the fertile period. The entire vagina gradually becomes tighter and shorter; the vaginal epithelium becomes brittle, often bleeding even after minimal trauma. Similarly, the vulvar area became atrophic and more vulnerable.⁴

Typical symptoms of vulvo-vaginal atrophy (VVA) are vaginal dryness, itching, burning, soreness, dysuria, dyspareunia, incontinence, nycturia, and frequent cystitis.^{5,6}

¹Department of Obstetric and Gynecology, Hospital State of Republic of San Marino, San Marino, Republic of San Marino.

²Department of Dermatology, University of Rome Tor Vergata, Rome, Italy.

³Dermatology Center srl, Bologna, Italy.

⁴“Laser in Dermatology,” University of Rome Tor Vergata, Rome, Italy.

⁵Section of Dermatology, Department of Surgery and Translational Medicine, University of Florence, Ospedale “Piero Palagi,” Florence, Italy.

⁶Division of Plastic Surgery, S.Orsola-Malpighi University Hospital Bologna, Bologna, Italy.

⁷Dermatology Department of Health Sciences, “Magna Grecia” University of Catanzaro, Catanzaro, Italy.

VVA gets gradually worse over the years and certainly has an important impact on the patients' quality of life.

Many treatment protocols have been proposed over the past few years to improve VVA symptoms, such as non-hormonal drugs in mild cases and topical or systemic hormonal therapy in medium-to-severe disease activity.^{7,8} The systemic treatment could significantly improve the symptoms, but sometimes there are many contraindications and side effects.⁸⁻¹⁰ Moreover, the symptoms reappear after these therapies are interrupted.^{11,12}

In a study, conducted by Gaspar et al., the vaginal epithelium of 92 patients was treated with micro-fractional CO₂ laser, combined with platelet-rich plasma, achieving great results in terms of improving VVA; the results were evaluated by vaginal biopsy performed both before and after treatment, demonstrating improvement in all three layers of the vaginal epithelium.¹³

A similar study, conducted in 2013 by Salvatore et al., showed an improvement of VVA symptoms and VH1 scores after the 12-week follow-up.

Another recent and interesting application of CO₂ laser is for the treatment of vulvar lichen sclerosus atrophicus (LSA). LSA is a chronic skin disease with unknown etiology that involves the external genitalia. Most of the patients are postmenopausal women, but this pathology could also affect men and children.

Patients reported the same symptoms linked to vaginal atrophy and significant symptoms related to vulvar involvement.¹⁴

The application of laser therapy to induce a vaginal rejuvenation can help women affected by LSA eliminate these symptoms and, thus, significantly improve their quality of life.

Materials and Methods

Patient population

In our study, which took place from January 2013 to January 2015, we enrolled 386 menopausal patients (age range, 48–56 years old) (Table 1), with symptoms due to the vaginal atrophy (i.e., dryness, itching, burning, dyspareunia) and not after hormone therapy. Sixty-three were also affected by LSA. Infection investigations in all women were negative.

All patients filled in a visual analog scale questionnaire; before the first and after the second and third treatment, they had to indicate a value from 1 to 10 (where 1 meant no symptoms and 10 meant the maximum effect of the symptoms) about laxity symptoms, vaginal dryness, irritation-burning, and dyspareunia.

Vaginal laser resurfacing

The CO₂ laser has a wavelength of 10,600 nm and uses a mixture of CO₂, N, and He as active medium.⁵⁻¹⁰ Its target

TABLE 1. PATIENT AGE CHARACTERISTICS

Patient age (years)	No. of patients (%)
48–50	44 (12)
51–60	245 (64)
61–70	75 (20)
>70	22 (6)

TABLE 2. LASER SETTING FOR ENDOVAGINAL AND VULVAR TREATMENT

	Pulse	Power (watt)	Dwell time (msec)	Dot spacing (μm)	Stack
Endovaginal	DP	40	1000	1000	2
Vulva	DP	30	1000	1000	1

is intra- and extracellular water, which makes up 77% of the skin. The effect is a very high-energy absorption and minimal tissue penetration; also, it seals small nerve endings with pain reduction of the lymphatic vessels and with edema reduction of blood vessels with a hemostatic effect.

A new device, called SmartXide² (DEKA, Florence, Italy), introduces the use of the Vulvo-Vaginal Laser Reshaping procedure, which supplies energy with a dedicated pulse shape, called D-Pulse, derived from dermatological experience, but takes into account the peculiarities of the vaginal epithelium. The initial part of the D-Pulse involves constant and high peak power for rapid and painless superficial removal of the epithelial component of the atrophic mucosa that is characterized as having a low water content. A second variable part, with a lower peak power and a longer emission time, allows the laser energy to penetrate into the mucosa and stimulates it properly at depth.

The Stack mode also provides precise control of the vaporization depth in the skin and the thermal action. This technology delivers a number of successive pulses in the same point, from one to five, leading to a reduction of side effects.

Treatment

Gynecological evaluation was performed before treatment to assess the level of atrophy and subjective symptoms, to exclude prolapse of the pelvic organs that cannot be greater than the second degree, to rule out infections, and to perform a Pap test, which must be negative.

The CO₂ laser (SmartXide² V²LR, Monalisa Touch; DEKA) was set with a DOT (micro-ablative zone) power of 40 W, a dwell time of 1000 μsec, a DOT spacing of 1000 μm, and a Stack of 2. The laser probe was inserted into the vagina without speculum and without using lubricants or topical anesthetics. Patients reported only mild discomfort

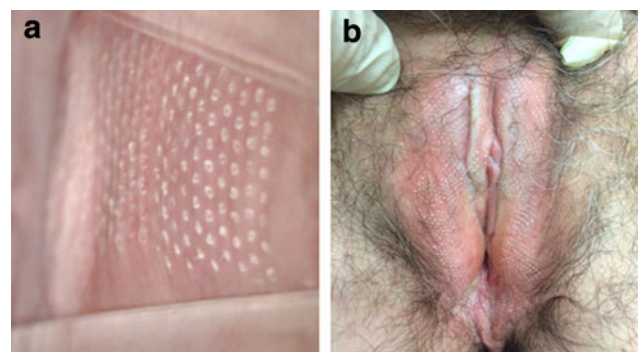


FIG. 1. (a, b) The vaginal and vulvar appearance immediately after fractional CO₂ laser treatment.

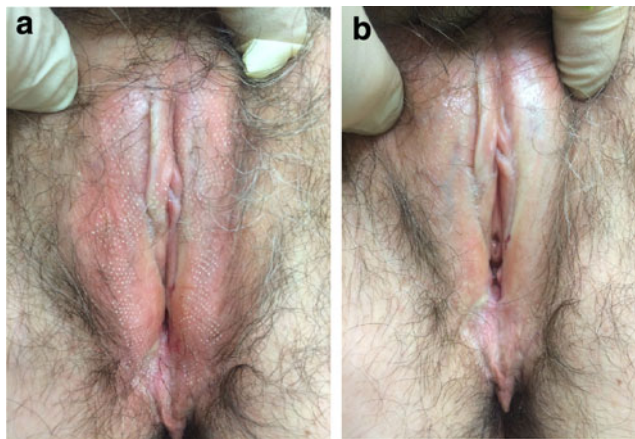


FIG. 2. (a, b) Picture of hypertrophic vulvar dystrophy: immediately after the first treatment (*left*) and 1 month after the third treatment (*right*). There is an evident improvement of the vulvar epithelium as well as a marked regression of the itchy symptoms.

during the insertion of the probe, but no pain during treatment. The treatment takes only a few minutes.

The treatment was then used on the vaginal introitus and vulva by using a fractioned scanner handpiece (SmartXide² V²LR, Vulvar Probe; DEKA). The laser was set to a DOT power of 30 W, a dwell time of 1000 μ sec, a DOT spacing of 1000 μ m, and a Stack of 1 (Table 2 and Fig. 1a, b).

Unlike vaginal treatment, which is considered painless, the vulvar treatment is quite painful. After treatment, patients were recommended to use a moisturizing cream and re-epithelializing eggs. Hot baths and sexual activity were not recommended for 24 h.

Results

A total of 386 patients were treated from January 2013 to January 2015.

Although the protocol involved three laser applications, many patients began to see an improvement already after the first treatment, especially in patients with just vaginal symptoms, due to vaginal atrophy, without dyspareunia and LSA. (Fig. 2a, b)

The main reported side effect experienced during treatment was discomfort during the insertion of the probe, minimum blood-serum secretions for 1–2 days, and mild burning for 1–2 h after treatment. No pain during treatment was reported in 764 of the 1158 total applications (Table 3).

TABLE 3. SIDES EFFECTS REPORTED DURING VULVAR-VAGINAL CO₂ FRACTIONAL FIRST TREATMENT

Side effects during treatment	n (%)
None	764 (66)
Burn sensation	127 (11)
Bother during the handpiece movement	70 (6)
Pain during handpiece movement	58 (5)
Vulvar introitus pain	58 (5)
Vulvar introitus burn	46 (4)
Vulvar pain	35 (3)

TABLE 4. SYMPTOM REDUCTION 2 MONTHS AFTER THREE TREATMENTS

Symptom	n (%)
Vaginal dryness	231 (59.94)
Vaginal burning sensation	216 (56.26)
Dyspareunia	190 (48.75)
Itching	220 (56.37)
Soreness	281 (73.15)
Vaginal introitus pain	185 (48.79)

After three treatments, patients reported a complete improvement of the symptoms (59.94% dryness, 56.26% burn sensation, 48.75% dyspareunia, 56.37% itch, 73.15% soreness, and 48.79% vaginal introitus pain) (Table 4).

After the first session, patients already reported feeling lubrication similar to that before menopause; had an improvement in the burning, discomfort, itching, and dryness symptoms; and were again able to have painless and satisfactory sex. Half of the patients treated reported a good improvement in the urinary symptoms after treatment (urgency, dysuria, incontinence, cystitis). This aspect was not considered in the questionnaire, but it was spontaneously reported by the patients.

Discussion

During their lifetime, 76% of women report a decreased genital sensation with impaired sexual function and psychological discomfort.^{15,16} Several methods were reported to induce a vaginal rejuvenation, both surgical and nonsurgical.

The aim of surgery is to treat aesthetic problems, such as hypertrophied labia minora, redundant labia majora, or hypertrophic clitoral hood folds, as well as functional problems such as laxity or widened vagina.

The most commonly used procedures were labioplasty, reduction of the clitoral hood, vaginoplasty, and perineoplasty. The use of synthetic or autologous materials, such as lipofilling, was also described for treating vaginal widening, but this procedure was linked with the risk of infection, which can then lead to several problems.

This technique reported good outcomes, with a fairly low incidence of complications. The reported techniques tried to restore the anatomy of the vagina, reducing the widening that occurs during a woman’s lifetime. The main problem is that these procedures cannot be used on vaginal atrophy linked to menopause or pathologic conditions, such as LSA.

In these cases, a true vaginal rejuvenation needs to occur to restore vaginal function, improving sexual activity, reducing the symptoms, and, thus, improving the patient’s quality of life. The introduction of laser treatment in this field seems to be the best method to obtain all these results.¹⁶

Our experience demonstrated that fractional micro-ablative CO₂ laser is useful for treating the vaginal epithelium. The use of the fractional micro-ablative CO₂ laser on the vaginal mucosa was immediately associated with initial tissue remodeling, which leads to the foundation of its clinical application. It also allows us to contemplate promising results as previously described in many areas of the human body, such

as the skin on the face, chest, and neck and in animal models, including the production of new collagen and other components of the extracellular matrix. The mechanism of these changes was recently proven.¹⁷

The vaginal epithelium is characterized by the absence of keratin and the presence of a high water content. Tissue damage caused by the micro-ablations and heating of the CO₂ laser stimulates fibrocytes to return to being productive fibroblasts that can restore the correct composition of collagen fibers within the amorphous substance with adequate water content.

The effects of the fractional CO₂ laser on the mucosa can be summarized in a central zone of vaporization, an intermediate zone characterized by denaturation and contraction of the collagen fibers, which creates a thermal barrier for the underlying mucosa, and a peripheral zone of hyperthermia. In this latter area, the heat activates the heat shock proteins, in particular HSP 43-47-70. These proteins induce a local increase in different cytokines: transforming growth factor- α , basic fibroblast growth factor, epidermal growth factor, platelet-derived growth factor and vascular endothelial growth factor, stimulating matrix proteins such as collagen, angiogenic activity with endothelial cell migration and proliferation, re-epithelization, regulating neo-angiogenesis, and activating fibroblasts to produce new collagen and other components of the extracellular matrix. Using a polarized light, a layer of small collagen fibers generated by the denatured collagen can be highlighted. So the laser also works at depth without causing irreversible damage. In fact, the fibers are of small caliber and intact.¹⁸

The final effect is to restore the correct permeability to the connective tissue. The increase in nutrients that reach the mucosa improves vaginal wall turgor; the hydration reduces itching and burning, increasing vaginal transudate that decreases dryness and dyspareunia and the recovery of mucosa tropism, with an increase of intracellular glycogen, leading to colonization by lactobacilli and a decrease in vaginal pH.

Histological studies performed 1 month after a single laser treatment show that the vaginal mucosa had a significantly increased thickness, with detachment on the cell surface and increased glycogen.

The improvement reported in urinary symptoms cannot be easily explained and no bibliographic references were present, but they were largely reported in our series. The side effects reported during treatment and the very low incidence of complications, which spontaneously disappeared, led us to consider that the laser treatment is safe.

We have shown the effects of fractional micro-ablative CO₂ laser treatment in a large series of patients. The side effects reported by patients were very low, and the positive results were confirmed by all the patients.

To face the possible side effects and to ensure a multidisciplinary approach, gynecology and dermatology should be the specialties with legal responsibility for the procedure. Moreover, a careful selection of patients and a strict follow-up are crucial to manage complications.

Conclusions

The fractional micro-ablative CO₂ laser seems to be effective in reducing symptoms related to vaginal atrophy. The effects of the treatment led to the recovery of a normal

mucosal surface and function. The beneficial effects were reported after just the first session and were confirmed 2 months after the previous session. The treatment is quite comfortable and painless.

There are still many questions, for example, the long-term duration of this treatment. We have a maximum of 2 years follow-up experience, which is the same as that reported in previous studies.^{19,20}

Comparative studies between CO₂ laser treatment and vaginal use of topical estrogens are still lacking.

In conclusion, fractional micro-ablative CO₂ laser represents a valid treatment on VVA in postmenopausal women, but further studies are required to achieve a validated protocol and to evaluate the long-term efficacy.

Author Disclosure Statement

No competing financial interests exist.

References

- Campolmi P, Bonan P, Cannarozzo G. Laser e sorgenti luminose in dermatologia. Masson (ed.), Milano, 2003, 17–40.
- Sturdee DW, Panay N; International Menopause Society Writing Group. Recommendations for the management of postmenopausal vaginal atrophy. *Climacteric* 2010;13:509–522.
- Freedman M. Vaginal pH, estrogen and genital atrophy. *Menopause Management* 2008;17:9–13.
- Mehta A, Bachmann G. Vulvovaginal complaints. *Clin Obstet Gynecol* 2008;51:549–555.
- Panay N, Maamari R. Treatment of postmenopausal vaginal atrophy with 10- μ g estradiol vaginal tablets. *Menopause Int* 2012;18:15–19.
- Parish SJ, Nappi RE, Krychman ML, et al. Impact of vulvovaginal health on postmenopausal women: a review of surveys on symptoms of vulvovaginal atrophy. *Int J Womens Health* 2013;5:437–447.
- Archer DF. Efficacy and tolerability of local estrogen therapy for urogenital atrophy. *Menopause* 2010;17:194–203.
- Johnston SL, Farrell SA, Bouchard C, et al. The detection and management of vaginal atrophy. *J Obstet Gynaecol Can* 2004;26:503–515.
- Bygdeman M, Swahn M. Replens versus dienoestrol cream in the symptomatic treatment of vaginal atrophy in postmenopausal women. *Maturitas* 1996;23:259–263.
- Rees M, Pérez-lópez FR, Ceasu I, et al. EMAS clinical guide: low-dose vaginal estrogens for postmenopausal vaginal atrophy. *Maturitas* 2012;73:71–74.
- Barton DL, Ganz PA. Symptoms: menopause, infertility, and sexual health. *Adv Exp Med Biol* 2015;862:115–141.
- Fistarol SK, Itin PH. Diagnosis and treatment of lichen sclerosus an update. *Am J Clin Dermatol* 2013;14:27–47.
- Gaspar A, Addamo G, Brandi H. Vaginal fractional CO₂ laser: a minimally invasive option for vaginal rejuvenation. *Am J Cosm Surg* 2011;28:156–162.
- Perino A, Calligaro A, Forlani F, et al. Vulvo-vaginal atrophy: a new treatment modality using thermo-ablative fractional CO₂ laser. *Maturitas* 2015;80:296–301.
- Salvatore S, Nappi RE, Parma M, et al. Sexual function after fractional microablative CO₂ laser in women with vulvovaginal atrophy. *Climacteric* 2015;18:219–225.
- Stefano S, Stavros A, Massimo C. The use of pulsed CO₂ lasers for the treatment of vulvovaginal atrophy. *Curr Opin Obstet Gynecol* 2015;27:504–508.

17. Salvatore S, Leone Roberti Maggiore U, Athanasiou S, et al. Histological study on the effects of microablative fractional CO₂ laser on atrophic vaginal tissue: an ex vivo study. *Menopause* 2015;22:845–849.
18. Zerbinati N, Serati M, Origoni M, et al. Microscopic and ultrastructural modifications of postmenopausal atrophic vaginal mucosa after fractional carbon dioxide laser treatment. *Lasers Med Sci* 2015;30:429–436.
19. Salvatore S, Nappi E, Zerbinati N, et al. A 12-week treatment with fractional CO₂ laser for vulvovaginal atrophy: a pilot study. *Climacteric* 2014;17:363–369.
20. Longo C, Galimberti M, De Pace B, et al. Laser skin rejuvenation: epidermal changes and collagen remodeling evaluated by in vivo confocal microscopy. *Lasers Med Sci* 2013;28:76.

Address correspondence to:

Ester Del Duca
Department of Dermatology
University of Rome Tor Vergata
Viale Oxford, 81
Rome 00133
Italy

E-mail: ester.delduca@gmail.com

Received: June 19, 2016.

Accepted after revision: August 20, 2016.

Published online: December 30, 2016.